

Absent septum pellucidum and white matter alterations in a patient with Childhood Obsessive Compulsive Disorder: A case report

Dr. Ashwini Padmashali¹, Dr. Praveen Kumar², Dr. Suhas Chandran³

1,3- Dept. of Psychiatry, St John's medical college, Bangalore.2- Institute of Neurosciences, Kolkata.



BACKGROUND

- Congenital brain defect of agenesis of septum pellucidum is a rare finding.
- Septum pellucidum: A thin membrane located at the midline of the brain between the two cerebral hemispheres and connected to the corpus callosum.
- Agenesis of septum pellucidum accompanies various malformations of the brain that affect intelligence, behavior, seizures and learning disabilities.

CASE REPORT

- A 14 year old adolescent presented with history of academic decline since 2 years.
- Parents also reported that child had complains of repeated questioning, rereading, rewriting, repeatedly arranging curtains, t-shirt collar, pillows, repeated handwashing and patterned way of wiping hands.
- Delayed developmental milestones such as walking at 1 and ½ years and started speaking at 3 years with articulation difficulties.
- Diagnosed with hearing impairment at 6 years which showed left ear with profound hearing loss and right ear with moderate hearing impairment.
- Using hearing aids since 8 years.
- Temperamentally slow to warm child.
- Mother has history of anankastic personality traits.
- Authoritative parenting was present.

ON EXAMINATION

- GPE- Normal
- MSE – Obsessions of contamination, hoarding favorite food, obsessions for arranging things in sequence were noted. Compulsions of handwashing, overwriting words, arranging things present with impaired judgment and poor insight.

INVESTIGATIONS

- Blood investigations were within normal limit
- CY-BOCS score was 27 indicating moderate to severe OCD.
- WISC-IV -full scale IQ 98 suggestive of average intelligence.
- MRI Brain findings – Absent septum pellucidum and chronic microangiopathic changes in right corona radiata.

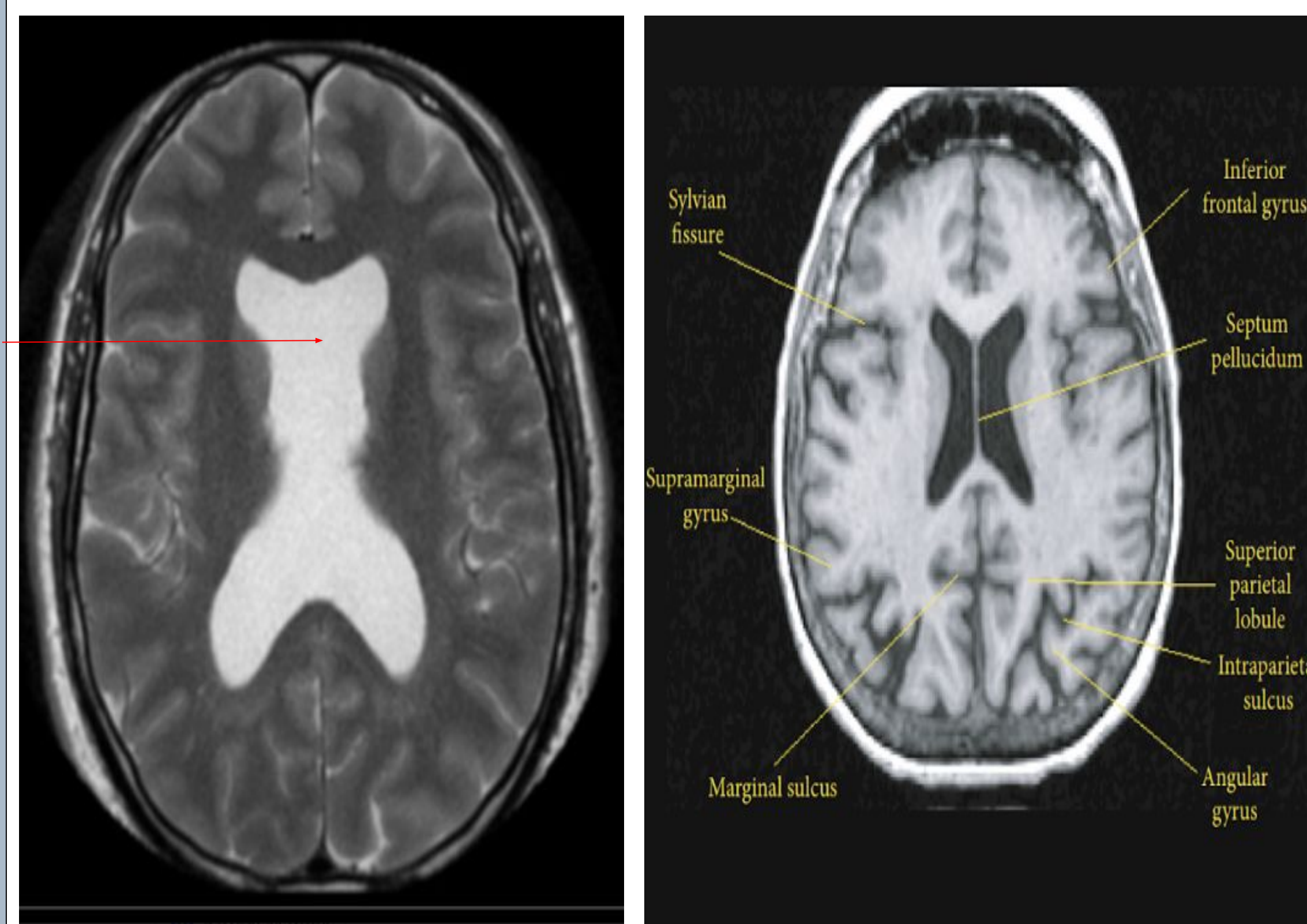


FIGURE 1

FIGURE 2

FIGURE 1: Axial MRI showing Absent Septum Pellucidum
FIGURE 2: Normal axial MRI

MANAGEMENT

- Initially evaluated elsewhere, already treated with Tab Fluoxetine 30 mg.
- In view of worsening of symptoms after using Tab Fluoxetine for 1 year, changed to Tab Fluvoxamine 100 mg.
- Brought to St John's Hospital for further evaluation and management.
- After detailed evaluation and drug review, plan was made to optimize the medications and start CBT for OCD.
- Currently on Tab Fluoxetine 70 mg

DIAGNOSIS

Axis I- Obsessive compulsive disorder- mixed
Axis II- Delayed language development
Axis III- Average Intelligence
Axis IV- B/I hearing impairment
Axis V- Inappropriate parental pressure on academic performance

DISCUSSION

- Large number of studies on OCD have detected structural and functional alterations in the brain.
- Besides cortico striato thalamo cortical circuit, alterations have been observed in other foci such as dorso lateral prefrontal cortex / medial prefrontal cortex, temporal, parietal and occipital regions, anterior insula and internal capsule.
- Besides these areas changes have also been noted in the white matter corpus callosum, cingulum bundle and parietal regions.
- Poor response to medications have been reported in the presence of structural abnormalities.
- This incidental finding raises questions about possible relationship between this brain structure and functions in neuropsychiatric pathology.
- Future research needs to consider if structural abnormalities of Septum pellucidum could be associated with poor response to treatment.

CONCLUSION

- Septum pellucidum and abnormalities in the white matter tracts may need to be evaluated in patients presenting with OCD and poor response to treatment.
- This case showcases the involvement of other brain structures that have not been routinely evaluated in OCD.

BIBLIOGRAPHY

1. Jayarajan et al. White matter abnormalities in children and adolescents with obsessive compulsive disorder: A diffusion tensor imaging study. Depression and Anxiety 0:1-9(2012)
2. Rosso et al. Brain white matter integrity and association with age at onset in pediatric obsessive-compulsive disorder. Biology of Mood and Anxiety Disorders 2014 4:13.
3. Fontenelle et al. Is there evidence of Brain white matter abnormalities in Obsessive compulsive Disorder? Top Magn Reson Imaging 2009;20:291-98

Conflict of Interest: None